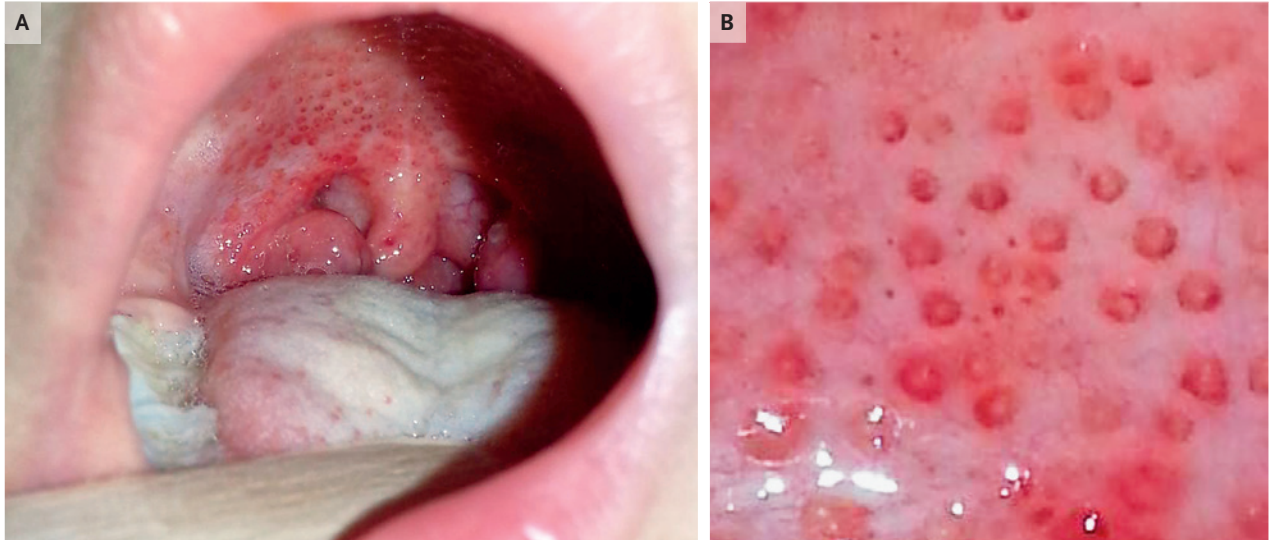


IMAGES IN CLINICAL MEDICINE

Chana A. Sacks, M.D., *Editor*

## “Doughnut” Lesions



**A**N OTHERWISE HEALTHY 9-YEAR-OLD GIRL PRESENTED TO THE PRIMARY care clinic with a sore throat and fever. Her temperature was 38.5°C. Physical examination revealed swollen and tender cervical lymph nodes, an inflamed uvula, enlarged tonsils, and “doughnut” lesions on both the hard and soft palates (Panels A and B). A rapid antigen detection test for group A streptococcus was positive. Throat culture confirmed group A beta-hemolytic streptococcus. “Doughnut” lesions are erythematous papules with a pale center that may be present on both the soft and hard palates. The presence of these lesions is a clinical sign that has historically been associated with group A streptococcus pharyngitis. The patient was treated with a 10-day course of oral amoxicillin and recovered without complication.

DOI: 10.1056/NEJMicm1810556

Copyright © 2019 Massachusetts Medical Society.

Akira Kobayashi, M.D.

Nanmei-kai Miyagami Hospital  
Kagoshima, Japan  
akirakobachan@msn.com

Hiromichi Iwasaki, M.D.

University of Fukui  
Fukui, Japan